



**The First Combined Meeting of
British Limb Reconstruction Society
&
British Society for Children's Orthopaedic Surgery**

26, 27 & 28 January 2011

Sheffield, UK

Sheffield Teaching Hospitals 
NHS Foundation Trust
Excellence as standard



**The First Combined Meeting of
British Limb Reconstruction Society
&
British Society for Children's Orthopaedic Surgery**

26, 27 & 28 January, 2011

Dear Delegate

On behalf of the British Limb Reconstruction Society & the British Society for Children's Orthopaedic Surgery, welcome to Sheffield and to our first combined meeting.

The aim of the conference is to provide you with a comprehensive overview of select topics with tips, tricks & pitfalls of limb reconstruction in adults & paediatrics through didactic lectures, discussions and hands on workshops. Also, the free paper sessions will stimulate discussion on various topics and also the opportunity for presenters from different centres and countries to update us with new research ideas and patient outcomes.

We have assembled a well renowned International and national Faculty of experts within the field, who are skilled and enthusiastic teachers. We are grateful to all of them for their time and presence. We are sure that there will be ample opportunity to mingle with faculty share thoughts and ideas as well as take back fond memories of this combined event.

The Gala Dinner on Thursday hopefully will satisfy your taste buds with some authentic Yorkshire cuisine.

We look forward to an enjoyable and thought-provoking course for all the faculty and delegates.

James Fernandes FRCS
Sheffield

Mark Flowers FRCS
Sheffield

Simon Royston FRCS
Sheffield

**Message from the President of the British Limb
Reconstruction Society**



Dear Members and Delegates,

It gives me great pleasure to welcome you to this combined meeting of the British Limb Reconstruction Society and the British Society for Children's Orthopaedic Surgery. As you will no doubt appreciate, there is a great deal of overlap in much of what we do and therefore the interaction afforded by this meeting I am sure, will be very welcome by all. The program is very interesting and full and should make this meeting educationally relevant and intellectually rewarding. I hope that your stay will be enjoyable and the contacts you make here long lasting.

Best Wishes.

Sunil Dhar



**The First Combined Meeting of
British Limb Reconstruction Society
&
British Society for Children's Orthopaedic Surgery**



26, 27 & 28 January, 2011

Programme

HOSTS

Mr James A Fernandes
Mr Mark J Flowers
Mr Simon Royston

International Faculty

Dr J-M Guichet, France
Prof Gamal Hosny, Egypt
Dr Dror Paley, USA
Prof Peter Stevens, USA
Dr Kevin Tetsworth, Australia

VENUE

Post-graduate Medical Education Centre

Northern General Hospital

Herries Road

SHEFFIELD

S5 7AU

www.sth.nhs.uk

Themes (Jan 26-27)

Complications of limb reconstruction surgery
Intramedullary lengthening nails
Limb salvage and Post-Traumatic Reconstruction

Theme (Jan 28)

Current topics on paediatric limb reconstruction

Wednesday 26th January, 2011

Time	Description	Faculty
PGME – Foyer , Northern General Hospital		
0815 – 0850	Registration, Coffee & Exhibition	
Lecture Theatre 2		
Session 1: Complications of limb reconstruction surgery		
Moderator: Mick Dennison		
0850 – 0900	Introduction & Housekeeping	J A Fernandes
0900 – 0915	Pin Site Infections, Prevention & Treatment	S Royston
0915 – 0930	Neurovascular Complications	S Jones
0930 – 0945	Muscle Contractures & Joint Problems	D Nayagam
0945 – 1000	The Regenerate & Fractures	J McGregor-Riley
1000 – 1015	Problems related to Monolateral Devices	M Saleh
1015 – 1030	Circular Hardware & Software Related Problems	S Giles
1030 – 1050	Discussion	ALL
1050 - 1120: Coffee and Exhibition, Foyer and 1st Floor UG room		
1120 – 1250	WORKSHOP on Computer Assisted Orthopaedic Surgery (CHAOS) SPONSORED by SMITH & NEPHEW	M Jackson F Monsell K Tetsworth
1250 – 1350: LUNCH and EXHIBITION – 1st Floor, Under graduate room and Foyer		
1350 – 1450: Breakout Sessions (Clinical cases – Adults, Paeds)		
Lecture theatre 1		Lecture theatre 2
Adults – S Royston D Nayagam C Andrews		Paeds – S Jones R Hill F Monsell
(Delegates are welcome to present interesting cases and unusual complications – Handover to appropriate Leads in the morning on PowerPoint 2007, 6 slides)		

Time	Description	Faculty
Session 2: Intramedullary lengthening nails		
Moderator: J A Fernandes		
1450 – 1520	History, Technology of Lengthening & the Albizzia	J-M Guichet
1520 – 1540	The UK Experience of Femoral Lengthening	H Simpson
1540 – 1600	The Australian Experience of Lengthening Nails	K Tetsworth
1600 – 1630	Cosmetic limb lengthening: Indications, Results and Psychologic considerations	D Paley
1630 – 1650	Discussion	ALL
1650 – 1710	Tea & Exhibition, Foyer and 1st Floor UG Room	
1710 – 1830	WORKSHOP on ISKD SPONSORED by ORTHOFIX (1 st Floor UG Room)	H Simpson D Paley R Hill
1830	CLOSE	
Free Evening		

Thursday 27th January, 2011

Time	Description	Faculty
0800 – 0830	Registration, Coffee & Exhibition	
Lecture Theatre 2		
Session 3: Select Topics on Limb Salvage and Post-Traumatic Reconstruction		
Moderator: S Royston		
0830 – 0900	Osteomyelitis and infected nonunions	M Dennison
0900 – 0930	Current perspectives on limb salvage with special reference to “LEAP project”	K Tetsworth
0930 – 0950	Post traumatic reconstruction in the tropics	G Hosny
0950 – 1010	Tibial plateau malunions	K Tetsworth

Time	Description	Faculty
1010 – 1030	The Biology of BMP and a rational approach to it's usage in Paediatric Orthopaedics	D Paley
1030 – 1045	Discussion	ALL
1045 – 1115	Coffee and Exhibition, Foyer and 1st Floor UG room	
1115 – 1230	WORKSHOP on Fine Wire Foot Frames with the Circular Fixator SPONSORED by ORTHOSOLUTIONS (1 st floor,UG room)	O Lahoti S Jones A Khaleel
1115 – 1230	AHP's Breakout session Lecture Theatre 1	J Pagdin M Vincent T Johnston
1230 – 1400: LUNCH and EXHIBITION - 1st Floor, Undergraduate room and Foyer		
1315 – 1400: BLRS AGM 2011, Lecture Theatre 1		
SESSION 4: Presidential Invited Lectures		
Moderator : S Dhar		
1400 – 1415	The Presidential Invited Guest Lecture “ASAMI International and it's future directives”	Prof G Hosny
1415 – 1430	The Presidential Invited Lecture “ Late reconstruction following severe ankle injury”	Prof M Saleh
Free Papers: Session 1, Best Paper section		
Moderator: Steve Giles		
1430 – 1437	Cost analysis of Complex tibial fractures treated with Circular Frames	R Rambani Hull
1437 – 1447	Comparison of three Anaesthetic Techniques to Provide Post Operative Analgesia in Children following Application of Circular Fixtor for Limb Reconstructive Surgery	E Wells-Cole Manchester
1450 – 1457	Forearm Lengthening in Children. Review of 22 Cases	R A Hill London
1500 – 1507	Gait Characteristics of Achondroplasia following Lower Limb Lengthening	J van der Meulen Sheffield

Time	Description	Faculty
1510 – 1517	Gentamycin – Collagen Sponge for Treatment of Bone Infection: Short & Intermediate Term Results	G El-Adl Cairo
1520 – 1527	The role of Exogen bone stimulator in delayed and non unions	S S Sarmah Hull
1530 – 1550	Tea and Exhibition, Foyer and UG room 1st floor	
Free Papers: Session 2		
Moderator: M Ong		
1550 – 1555	Use of Recombinant Human Bone Morphogenic Protein – 2 in Children	K Saldanha Sheffield
1555 – 1600	A Novel Method to Encourage Children to Weight Beat after Frame Surgery – A Kinetic Analysis	L Streeton Oxford
1600 – 1605	A Novel Method for Monitoring Deformity Correction using 3-D Infra-red Camera Technology	S Abram Oxford
1605 – 1610	Lower Limb Lengthening for Disproportionate Short Stature: What are the Effects on Physical Function & Quality of Life?	M Burton Sheffield
1610 – 1620	Discussion	
1620 – 1625	Distraction Histogenesis in Relapsed & Neglected Clubfeet	M Fadel Cairo
1625 – 1630	Functional Outcome of Salvage of Residual & Recurrent Deformities of Clubfoot with Ilizarov Technique	H. El-Mowafi Egypt
1630 – 1635	Slipped Upper Tibial Epiphysis causing Tibia Vara – A Study of Three cases from Three Centres	A P Sanghrajka Sydney
1635 – 1640	Tibial Physeal Involvement & Fibular Sparing: Late Sequelae of Meningococcal Septicaemia	R A Hill London
1640 – 1650	Discussion	

Time	Description	Faculty
Free Papers: Session 3		
Moderator: J McGregor-Riley		
1650 – 1655	Cost of Physiotherapy Treatment of Ilizarov Frames	E Barron Hull
1655 - 1700	Fixation & Slippage of Kirshner Wires in Ilizarov External Fixators	M Zenios Manchester
1700 – 1705	Telesurveillance of Circular Frame Pin-sites: A One-year Experience at a Specialist Unit	S K Khan Leicester
1705 - 1715	Discussion	
1715 - 1720	Transverse Bone Transport using Ilizarov Principles	M Fadel Cairo
1720 – 1725	Ankle/Hindfoot Salvage Arthrodesis using External Fixation	P Moras Portsmouth
1725 – 1730	Simultaneous Management of Hand to Knee & Shortening Problems in Poliomyelitis	A S Allam Egypt
1730 - 1740	Discussion	
1740	Prizes and summation	J Fernandes
1930 for 2000	Combined Gala Dinner “Baldwin’s Omega” Brincliffe Hill Sheffield S11 9 DF	Dress code – Casual Formal

Friday 28th January, 2011

Combined Meeting of BLRS/BSCOS

Time	Description	Faculty
PGME – Foyer		
0800 – 0850	Registration, Coffee & Exhibition, Foyer and 1st Floor UG Room	
Lecture Theatre 2		
Current Topics in Paediatric Limb Reconstruction		
Moderator: Michael J Bell		
0850 – 0900	Sheffield and the history of limb reconstruction	M Bell
KEY NOTE LECTURES		
0900 – 0930	“Guided growth” – An overview and newer applications	P Stevens
0930 - 0940	Discussion	
0940 – 1020	An update on Hip and Knee reconstruction in Congenital femoral deficiency	D Paley
1020 - 1030	Discussion	
1030 - 1100	Coffee and exhibition	
Moderator: S Jones		
1100 – 1125	Are lengthening nails safe and cost effective in Children	J-M Guichet
1125 – 1150	Miserable malalignment syndrome	P Stevens
1150 – 1215	Newer techniques in the treatment of Radial clubhand	D Paley
1215 – 1230	Discussion	All
1230 – 1400: LUNCH and EXHIBITION - 1st Floor, Undergraduate room and Foyer		
1315 – 1400: BSCOS Business Meeting, Lecture Theatre 1		

Time	Description	Faculty
PGME – Lecture Theatre 2		
Free papers: Session 1, Best Paper section		
Moderator: G Davies		
1400 – 1407	Sheffield Telescoping Rod Versus Rush Pin in the Treatment of Osteogenesis Imperfecta	Gamal Al-Adl Cairo
1410 - 1417	Redislocation & the Computerrised Tomography Evaluation of Developmental Dysplasia of the Hip	A Cooper Sheffield
1420 - 1427	Management of the Sequelae of Old Septic Hip of Infancy	A M Hefny Cairo
1430 - 1437	Closed Reduction and Open Soft Tissue Release for Bilateral Hip Dislocations	AG de Gheldere London
1440 - 1447	A Changing Pattern of Femoral Fractures in Osteogenesis Imperfecta with Prolonged use of Bisphosphonates	N Nicolaou Sheffield
1450 - 1457	Experience & Complications Associated with the Fassier-Duval Telescoping Nailing System	A Vooght Liverpool
1500 - 1530	Tea & Exhibition	
Free Papers: Session 2		
Moderator: M Flowers		
1530 - 1535	A Review of the Role of External Fixators in Paediatric Trauma at the Royal London Hospital	J Humphrey London
1535 - 1540	Complex Foot Deformities in Children & Taylor Spatial Frame Correction	C J Edwards Southampton
1540 - 1545	Congenital Pseudarthrosis of the Tibia: A Single Surgeon Series of 19 Children	A Ghassemi London
1545 - 1556	Discussion	
1556 - 1601	Intraosseous Access and Amputation	C C Taylor Southampton
1601 - 1606	A Case Series Review of the Orthopaedic Problems Associated with Pseudoachondroplasia	N Siddiqui London

Time	Description	Faculty
1606 - 1611	Cyst Fluid & Stem Cells: Why Unicameral Bone Cysts are so Hard to Treat	A Aarvold Southampton
1611 - 1617	Discussion	
1617 - 1622	Consistency in Rating Criteria for the Diagnosis of Development Dysplasia of the Hip among Members of British Society for Children's Orthopaedic Surgery (BSCOS)	A Roposch London
1622 - 1627	Bilateral CDH Outcomes & Complications Analysis	V Goriainov Southampton
1627 - 1631	Discussion	
1631 - 1636	Congenital Radioulnar Synostosis – A new Operative Technique in Achieving Functional Supination Pronation Range	A S Allam Egypt
1636 - 1641	Legg-Calve-Perthes: Interobserver & intraobserver reliability of the modified Herring lateral pillar classification	R Rajan Derby
1641 - 1646	Consideration of the Oblique Plane Deformity in Slipped Upper Femoral Epiphysis	C J Geddis Sheffield
1646 - 1652	Discussion	
1652 - 1700	Prizes and summation	M Flowers
1700	Meeting Concludes	

THURSDAY, 27th January 2011
FREE PAPERS
SESSION 1- BEST PAPER SECTION

MODERATOR: STEVE GILES

COST ANALYSIS OF COMPLEX TIBIAL FRACTURES TREATED WITH CIRCULAR FRAMES

R Rambani, BM Lambden, M Fortnam, E Barron, Y Hadland, J Singh, HK Sharma
Department of Orthopaedics Hull Royal Infirmary Hull

Background Complex tibial fractures are difficult to treat. The costs associated with hospitalization can be substantial, yet it is unknown how these vary depending upon the type of implant used. There have been multiple studies on economics of tibial fractures but none of these studies actually focussed on costing of illizarov and taylor spatial frames. We discuss the cost analysis of 200 tibial fractures treated with illizarov or taylor spatial frames. The purpose of this study was to compare the cost of treatment of complex tibial fractures with reimbursement given to the hospital in treating such injuries.

Methods We evaluated the economical data of 200 patients with complex tibial fractures treated with illizarov frame or taylor spatial frame from May 2005 to may 2010. Demographic data, fracture classification and method of surgical treatment along with the length of hospital stay were recorded in detail. The total cost calculated was then compared to the range of reimbursement price based on HRG (human Resource Group) coding. The implant cost was determined from the buying cost of institution.

Results All fractures were sub-classified based on AO classification. Average age of the patients operated was 43.4 years. 30 percent of the patients had multiple bone fractures. 196 fractures healed in a mean time of 18.3 weeks. The average cost of treating isolated tibial fracture with illizarov frame was 5058.2 pounds. The average cost of treating tibial fractures in a polytrauma patient was 18285.4 pounds in our series. The reimbursement to the hospital varied considerably ranging from 1600 pounds to 13000 pounds.

Conclusion Hospital source utilization for tibial fractures treated with illizarov and TSF is quite high compared to the reimbursement being given to hospitals for treating such patients. This can be as low as £ 1600 as acute phase tariff to 13000 pounds in poly trauma patients and the implant cost can vary from 20% to 150% of the total reimbursement cost. Current recording system for these fractures is unclear resulting in discrepancy between resource utilization and reimbursement thus resulting in substantial loss of remuneration for hospitals that perform these procedures.

COMPARISON OF THREE ANAESTHETIC TECHNIQUES TO PROVIDE POST OPERATIVE ANALGESIA IN CHILDREN FOLLOWING APPLICATION OF CIRCULAR FIXATOR FOR LIMB RECONSTRUCTIVE SURGERY.

E Wells-Cole, F Ali, D Fines, A Griffiths, M Zenios
Royal Manchester Children's Hospital, Manchester.

The aim of this retrospective study is to compare the different anaesthetic techniques in children undergoing circular frame application for lengthening and deformity correction. Data was collected from 68 cases on severe pain episodes, post-operative duration of analgesia, requirement for top-up analgesia, complications and side-effects and number of osteotomies. The three analgesic methods used were morphine infusion (M), epidural analgesia (E) and continuous peripheral nerve blocks (CPNB). There was a significant difference between the number of episodes of severe pain experienced by the patients receiving a morphine infusion when compared to the epidural and CPNB groups (M vs. E $p < 0.0001$, M vs. CPNB $p = 0.018$). CPNB were associated with the lowest incidence of severe pain episodes and top-up analgesia requirements. The difference in the incidence of nausea and vomiting between the methods was approaching significance ($p = 0.06$). A significant difference was found when comparing epidural and morphine infusions ($p = 0.05$). Epidural analgesia was associated with significantly more nausea and vomiting ($p = 0.023$), and motor blockade ($p < 0.01$) than CPNB. The results show the most effective method of post-operative analgesia for our paediatric patients, in light of pain episodes and associated side-effects, is sciatic nerve catheterisation with continuous infusion.

FOREARM LENGTHENING IN CHILDREN REVIEW OF 22 CASES

R A Hill FRCS

Hospital for Sick Children, Great Ormond Street, London WC1N 3JH

This study retrospectively reviews all forearm lengthenings carried out by the author in order to assess results and complications and determine the efficacy of this treatment in children with various pathologies.

The records of all patients who had undergone a forearm lengthening between 1995 and 2009 were reviewed. 23 forearm lengthenings in 20 patients were identified but in one case there was insufficient information for the study. The study is therefore based on 22 lengthenings. The patients were divided into two groups, Group A in whom the purpose of treatment was to restore the length relationship between the radius and ulna and Group B in whom the purpose was to gain forearm length. In Group A patients the aim was to protect the radial head against dislocation by lengthening the ulna (with if necessary a corrective radial osteotomy) or to protect the wrist from subluxation by a radial lengthening. In Group B patients the aim was to improve function and cosmesis.

The average age of the patients at time of surgery was 9.78 years, average follow up was 26 months post frame removal. There were 11 patients in Group A with an average radio ulnar discrepancy of 2.34 cms and 11 patients in Group B. In Group A patients the average length achieved was 2.69 cms i.e. overcorrection and in Group B the average lengthening was 3.84 cms. In Group A patients lengthening was only partially successful at preventing subluxation or dislocation of the radial head. Common complications were pin site infection and poor regenerate formation.

Forearm lengthening by distraction osteogenesis is a worthwhile procedure in paediatric patients with improved cosmesis and function particularly in Group B patients.

GAIT CHARACTERISTICS OF ACHONDROPLASIA FOLLOWING LOWER LIMB-LENGTHENING

Jill van der Meulen, Wendy Dickens, Maria Burton, Anand Kumar, K Devalia, Stan Jones, James A Fernandes

Paediatric Limb Reconstruction Service
Sheffield Children's Hospital
Sheffield
S10 2TH

Aim

The aim of the study was to characterise gait in patients with achondroplasia post lengthening.

Patients/Materials and Methods

Full kinematic and kinetic lower limb gait analysis was performed at the Sheffield Children's Hospital gait laboratory, Sheffield, using a Vicon system (6 cameras working at 50Hz) and processed using Plug In Gait modelling software. The lengthened Achondroplasia group (n=11, mean age = 24.5 ± 6.1) had previously undergone surgical lengthening of the legs. The lengthened Achondroplasia group was compared to a control group of 11 adult normal subjects. Results

Averaged sagittal plane kinematics are shown in Figure 1. The key sagittal plane characteristics we found were increased anterior pelvic tilt (Achondroplasia mean = $22.2 \pm 7.1^\circ$, normal mean = $14.2 \pm 5.3^\circ$), decreased peak hip extension (Achondroplasia = $10.5 \pm 11.2^\circ$, normal = $-5.8 \pm 5.3^\circ$), increased peak hip flexion (Achondroplasia = $49.3 \pm 9.8^\circ$, normal = $40.0 \pm 5.2^\circ$), and reduced knee extension in midstance (Achondroplasia = $14.0 \pm 8.5^\circ$, normal = $4.4 \pm 8.5^\circ$) At the ankle the mean of the lengthened Achondroplasia group lies within one standard deviation of the normal dataset throughout the gait cycle.

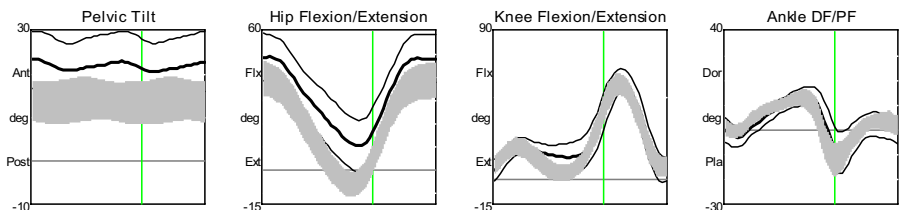


Figure 1: Averaged Gait kinematics including one standard deviation of the lengthened Achondroplasia group (line) against a normal adult group (shaded)

Summary and Conclusions

Three dimensional gait analysis of people with Achondroplasia following lower limb-lengthening surgery showed characteristic Achondroplastic gait, that is: increased anterior pelvic tilt, reduced hip extension and increased hip flexion. The group of lengthened Achondroplasia participants also failed to extend the knees fully in midstance. At the ankle the sagittal plane kinematics were within one standard deviation of the normal dataset.

GENTAMYCIN - COLLAGEN SPONGE FOR TREATMENT OF BONE INFECTION; SHORT AND INTERMEDIATE-TERM RESULTS

Gamal EL- ADL

From Mansoura University Hospital, Egypt

Aim: A prospective study to report the results of using gentamycin-collagen in the surgical treatment of osteomyelitis.

Materials and Methods: After complete radiological and laboratory studies, empirical systemic Imipenem antibiotic was started pre-operatively followed by radical operation and implantation of Collatamp-EG®. Bone defects were treated with iliac or composite ceramic bone graft. Primary or secondary soft tissue reconstructive procedures were used. Closed gravitational suction drainage was used. Parental systemic antibiotics were continued for 2-3 weeks according to culture sensitivity results followed by oral therapy for another 4 weeks. Cattaneo et al scoring system was used to evaluate the final bony and functional results.

Results: The mean number of Collatamp-EG® sponges implanted per patient were 3.6 and the mean follow-up period was 3.8 years. 85.7% of patients had showed positive cultures and staphylococcus aureus was the commonest cultured organism. The following complications were reported; pathological fracture (1), malunion (2), nonunion (1). According to Cattaneo et al scoring system, bone healing was achieved in 94.4% of patients; bone infection control without relapse was achieved in 100% of patients. 89.2% of patients had complete functional recovery.

Conclusions: Local antibiotic delivery system seems to be a useful and safe component in the armamentarium of the orthopedic surgeon dealing with bone infection by maximizing the local concentration while minimizing their systemic toxicity. Collatamp-EG® help bone and soft tissue repair without the need to remove it.

THE ROLE OF EXOGEN BONE STIMULATOR IN DELAYED AND NON UNIONS

Mr S S Sarmah, Dr C Fenton, Mr R Raman, Mr S Gopal, Mr N Roy, Mr H K Sharma
Hull Royal Infirmary

Purpose of study: The aim of this study is to evaluate the role of low intensity pulsed ultrasound, Exogen in the treatment of delayed and non unions.

Methodology: We conducted a retrospective study of 292 patients who has had Exogen treatment for delayed and non union from 2005 to 2009. Patient's age, sex, associated co morbidities, smoking history, medications, type of fractures (open/closed), infection and site of fractures were sought for. 271 patients' data (228 delayed and 43 non unions) were available during the study with mean age of 53.5 yrs.

Exogen therapy was initiated at 3-4 months for delayed unions and 6-12 months for non unions in 61 tibia (15 open); 31 femur (2 open); 20 scaphoid ; 38 5th metatarsal ; 31 ankle (2 open); 17 ulna (1 open); 15 radius (3 open); 29 humerus (2 open); 16 clavicles ; 6 olecranon ; 4 pilon (2 open) and 2 metacarpal fractures.

Discussion: Union was achieved in 196 patients (72.3%) of which 11 (5.6%) were smokers. In 73 (26.9 %) patients union was not achieved of which 53 (72 %) were smokers. The mean healing timing after application of Exogen was 16 weeks for delayed union and 26.6 weeks for non union. 5 (31.2%) pt out of 16 in the DM group went into non union.

Conclusion: In our study we found an accelerated union rate with Exogen therapy in delayed union, however smoking is a negative predictor for bone healing, which appears to be unaltered despite Exogen therapy($p=0.0032$). Prescribing Exogen therapy early may be potentially beneficial to prevent an established non union.

FREE PAPERS
SESSION 2
MODERATOR: MENG ONG

USE OF RECOMBINANT HUMAN BONE MORPHOGENIC PROTIEN - 2 IN CHILDREN

K Saldanha, S Madan, JA Fernandes, S Jones
Sheffield Childrens Hospital

Aim:

To study the results of using recombinant human bone morphogenic protein-2 (rhBMP-2) to achieve bone union in children with complex orthopaedic problems including skeletal dysplasia, congenital limb deficiencies and complex trauma.

Materials & Methods

Between November 2006 to April 2010, rhBMP-2 was used to achieve bone healing in a total of 19 children. The indications were delayed union or non-union in 16 long bones where previous surgeries had failed and 4 posterior spinal fusions. All children had underlying complex orthopaedic problems predisposing them to delayed bone healing. The average age at the time of surgery was 13years and 8 months (Range: From 4 years to 19 years and 4 months). There were 7 boys and 12 girls.

Results:

Average follow-up period was 9.6 months (Range: From 3 months to 2 years and 2 months). Out of the 16 long bone non-unions treated with rhBMP-2, 13 united without further interventions but 3 required further intervention. The average time for clinical union was 10 weeks (Range: from 6 weeks to 18 weeks). The average time for radiological union was 15 weeks (Range: from 7 weeks to 27 weeks). Two children who underwent instrumented posterior spinal fusion and two children who underwent uninstrumented spinal fusion achieved radiologically evident spinal fusion at an average of 16 weeks.

No local or systemic complications attributable to BMP were noted in any of the children.

Conclusions:

rhBMP-2 can be used successfully to achieve bone healing in long bone nonunion and delayed union and posterior spinal fusion in children with complex orthopaedic problems including skeletal dysplasia, congenital limb deficiencies and complex trauma. Its use in children has shown no unwanted effects in the short term.

Significance:

rhBMP-2 has been approved by Food and Drug Administration (FDA) as a bone graft substitute in adults. Its use in adults has been widely reported but there are only a few case reports of its use in children. This study shows that rhBMP-2 can be safely

A NOVEL METHOD TO ENCOURAGE CHILDREN TO WEIGHT-BEAR AFTER FRAME SURGERY– A KINETIC ANALYSIS

L Streeton, J Stebbins, AM Wainwright
Nuffield Orthopaedic Centre, Oxford

Purpose We describe a novel method to encourage children to weight-bear after frame surgery using a whoopee cushion; the objective of this study is to assess the amount of force taken through a limb using this method.

Design /participants The amount force is required to activate the whoopee cushion is measured when a subject takes weight through a whoopee cushion on a force plate. The speed of the foot in vertical and horizontal planes is assessed with motion analysis to correlate this to the activation of the cushion and is assessed under different conditions, and with different whoopee cushions

Results The average force required to reach the activation point was between 28N and 32N when only one cushion was strapped to the plantar surface of the foot. This is independent of the vertical speed of the foot, and of the horizontal walking speed. The use of shoes does not significantly alter the force required to reach the activation point. This force is a useful value to differentiate touch weight-bearing from partial weight-bearing. A child's weight-bearing status can be progressed if more than one whoopee cushion is used as the force needed increases.

Conclusions The whoopee cushion has been used in the rehabilitation of children to encourage weight-bearing after frame surgery. It will allow the child to distinguish between different forces expected for touch- and partial weight bearing, and can also be used to progress weight-bearing if more than one cushion is used.

A NOVEL METHOD FOR MONITORING DEFORMITY CORRECTION USING THREE-DIMENSIONAL INFRA-RED CAMERA TECHNOLOGY

S Abram, J Stebbins, T Theologis, A M Wainwright
Oxford Gait Laboratory, Nuffield Orthopaedic Centre, Oxford

Purpose The purpose of this study was to assess the accuracy of three-dimensional camera technology when monitoring deformity correction by an Ilizarov frame and to compare it to manual measurements.

Methods and Results A model consisting of an Ilizarov frame built around an artificial tibia and fibula was used with retro-reflective markers placed on the frame and bones to allow for the positions of each to be detected by the camera system. Measurements made by the camera system were compared to measurements taken manually.

In the assessment of frame lengthening, the camera system average error was 2% (SD 2%) compared to 7% (SD 6%) for manual measurement. In the assessment of bone lengthening, the camera system average error was 4% (SD 4%) compared to 34% (SD 8%) for manual measurement. The technology also demonstrated good accuracy in the measurement of angular deformity changes.

Conclusion The results of this study demonstrate that the measurement of deformity correction with three-dimensional infra-red camera technology is superior to manual measurements in a model of deformity correction. This method could replace or greatly reduce x-ray exposure in monitoring deformity correction post-operatively.

LOWER LIMB LENGTHENING FOR DISPROPORTIONATE SHORT STATURE:
WHAT ARE THE EFFECTS ON PHYSICAL FUNCTION AND QUALITY OF LIFE?
Authors: M. Burton, A.Gorva, K Devalia, W Dickens ,J van der Meulen, S. Jones,
J.A. Fernandes

Institute:
Paediatric Limb Reconstruction Service,
Sheffield Children's Hospital,
Western Bank,
Sheffield S10 2TH, UK

Abstract:

Purpose: To examine the effect of limb lengthening on the quality of life of people who have disproportionate short stature (DSS).

Method: Thirteen previous patients, completed the SF-36, the Derriford Appearance Scale and participated in face to face semi structured interviews to establish the impact on their physical and social functioning, their present situation including employment, education, housing and leisure activities and their thoughts about whether they felt the treatment had been worthwhile. To increase understanding about the patient and family experience of limb lengthening, participants were asked about their memories of the procedure and the treatment period.

Results: Much was learned about key areas such as pain control, pin site cleaning and physiotherapy. The importance of the role of families in supporting the patient through the treatment was strongly emphasised and how this was sometimes at the expense of siblings.

Conclusions: Overall all participants were able to find some benefit to the procedure but they had mixed feelings about the outcome. There was evidence of benefit to some physical capabilities and confidence levels but there were areas where the situation was similar to those with DSS who had not had surgery e.g. bodily pain. It is acknowledged that this study has some methodological weaknesses which reduce the strength of the findings.

DISTRACTION HISTOGENESIS IN RELAPSED AND NEGLECTED CLUB FOOT

Mohamed Fadel, MD

Department of Orthopedic Surgery, El-Minia University Hospital, Egypt

Conventional surgical treatment of relapsed or neglected club foot deformities is not always successful or easy to apply. The presence of shortened neurovascular structures and unhealthy skin may preclude the surgical interference. Bone resection in severe deformities results in short foot which is not satisfactory functionally and cosmetically.

Objectives: In this study we evaluate the use of the bloodless technique for management of relapsed or neglected club foot deformities.

Methods: From Jan 2000 -2006, 64 cases older than 2 years with relapsed or neglected club foot deformities were referred to our center. Four cases were excluded because of inadequate follow up data. This thesis based on 60 consecutive cases (67 feet). The patients average age was 8 years and 4 months (range, 2- 16 years). Seven cases were bilateral, 20 Left sides, and 34 Right sides. There were 57 relapsed club foot (5 bilateral), and 3 cases were neglected (2 bilateral). Patients with relapsed club foot had average 3 previous operations (range, 1-8 operations).

There was no preoperative assembling of the apparatus. The construct was designed according to the condition of deformity: equinus, varus forefoot etc. Additional procedures, elongation of tendoachilis was done concomitantly with the original procedure in 10 cases.

The patients were discharged from the hospital the same day of the operation

RESULTS

The range of operative time was 1 - 3 hours with an average of 1.5 hours. Average time in the fixator was 19.6 weeks (range, 10 weeks - 38 weeks). After fixator removal cast was applied for 2 months, followed by night splint and special shoes for their daily activities.

The average **follow-up period was 30.6 months (range, 12 - 84 months)** after fixator removal.

The results were: good in 55 feet, fair in 9, bad in 3.

Complications: All cases suffered from some sort of pin tract inflammation. For 8 cases: one of the wires had to be removed without anaesthesia due to persistent infection. For 3 cases: replacement of wires under general anaesthesia was performed. Oedema developed in the leg and dorsum of the foot or the ankle in 34cases. Frame adjustment under general anaesthesia in 3 cases. There are others such as: migration of the calcanean wire, 2 cases; over correction with valgus heel, two cases; flatfoot, 4 cases; talar subluxationin, 2 cases; talonavicular subluxation, one case; first metatarsophalangeal subluxation, 2 cases; flat topped talus, one case; broken wire, 2 cases and recurrence in 2 cases.

Discussion

It seems logic that osteotomy of the tarsus must be carried out whenever skeletal growth of the foot is at such an advanced stage that correction can not be established by means of articular repositioning and remodeling. However, equinovarus deformity of the foot in 65 adults (38 feet) was treated by external fixator without open procedure (Oganesyan et al, 1996). After an average follow-up 10 years, satisfactory results were obtained in all feet except four.

Conclusion

Ilizarov Treatment is lengthy, difficult, fraught with complications, and a technically demanding procedure. However, the complications did not affect the final outcome too much. Ilizarov method also offers the advantage of performing many additional procedures for other associated lower limb deformity. We believe that the bloodless technique using Ilizarov external fixator is an effective method in treating relapsed or neglected club foot deformities.

FUNCTIONAL OUTCOME OF SALVAGE OF RESIDUAL AND RECURRENT DEFORMITIES OF CLUBFOOT WITH ILIZAROV TECHNIQUE

H. EL-MOWAFI

Mansoura University Hospital, Mansoura Faculty of Medicine, Mansoura, Egypt

Purpose: The incidence of relapses could be occur in sever clubfeet deformities whether treated surgically or non surgically. In this study, we evaluate the results of correction of residual and recurrent congenital clubfoot with soft tissue distraction or osteotomy techniques using Ilizarov external fixation.

Methods: This study included 35 feet in 28 patients were treated between 1999 to 2007. 16 feet in thirteen patients with an average age 13.7 (range from 11-29 years) were treated with percutaneous calcaneal V steotomy and gradual correction by Ilizarov method. 19 feet in fifteen patients with an average age 10.5 (range from 4-22 years) were treated with distraction of joints through soft tissue with Ilizarov technique. The mean average follow up period was 5.6 years ranged from (1-8 years).

Results: At the time of fixator removal, a plantigrade foot was achieved in 30 feet. Mild residual varus and equines deformities were in 5 feet. At the last follow foot pressure measurement shows recurrent or residual deformity in ten feet (7 treated with bone osteotomy technique and 3 treated with soft tissue distraction technique).

Conclusion: We thought that recurrence may be occurred in both techniques this depends on many factor like the bone morphology, number of the pervious operations and the degree of stiffness of the foot prior the operation.

SLIPPED UPPER TIBIAL EPIPHYSIS CAUSING TIBIA VARA – A STUDY OF THREE CASES FROM THREE CENTRES

A P Sanghrajka¹, C Murnaghan³, H Simpson², M Bellemore¹, RA Hill³

¹The Children's Hospital at Westmead, Sydney, Australia

²Royal Infirmary of Edinburgh, Edinburgh, UK

³Great Ormond Street Hospital for Children, London, UK

Introduction

We report 3 cases from different centres of infantile tibia vara in which the deformity was due to slippage of the proximal tibial epiphysis on the metaphysis; the aim of this study was to define the features of this previously unreported condition, and their implications for management.

Method

Three cases of tibia vara secondary to atraumatic slippage of the upper tibial epiphysis on the metaphysis were identified from three different centres. The case notes and imaging studies were retrospectively reviewed to distinguish common clinical and radiographic features.

Results

There were one male and two females, all of non-Caucasian origin, (age 3-7 years). All patients' weights were above the 97th centile for age.

In all cases there was an infero-medial subluxation of the tibial epiphysis over a dome shaped proximal tibial metaphysis, with disruption of continuity between their lateral borders. The height of the medial tibial plateau was preserved in all cases. New bone formation suggests this is a chronic process. The evolution of one case indicates that pathogenesis is shared with infantile Blount's disease.

A gradual deformity correction was performed in all cases using circular external fixation, with the proximal ring secured to both the proximal epiphysis and metaphysis.

Conclusion

Slipped upper tibial epiphysis is an uncommon but distinct cause of tibia vara. The radiological features are completely different from those previously described for infantile tibia vara and not encompassed by the existing classification. The unusual morphology has consequences for treatment.

Management is analogous to a slipped upper femoral epiphysis – the physis has to be stabilized to the metaphysis and an osteotomy performed to restore the mechanical axis. We believe this is best achieved with a circular external fixator because this permits multiaxial correction including translation and rotation.

TIBIAL PHYSEAL INVOLVEMENT AND FIBULAR SPARING: LATE SEQUELAE OF MENINGOCOCCAL SEPTICAEMIA

RA Hill

Hospital for Sick Children, Great Ormond Street London WC1N 3JH

Aims Meningococcal septicaemia can result in growth arrest and angular deformities. The aim of this case series was to review the pattern of involvement in the lower leg.

Patients and Methods The notes and radiographs of all patients presenting with a growth arrest or deformity affecting the lower leg following meningococcal septicaemia between 1995 and 2010 were reviewed. There were fourteen patients, eight girls and six boys. The mean age of the patients at the time of presentation was 9.6 years.

Results There was a variety of deformities with some patients exhibiting several deformities in the same limb and/or bilateral deformities. Some of the deformities were complex. Nine patients had a lower limb length discrepancy (mean 4.8cms, range: 1 to 13cms). There were a total of 27 lower limb deformities; three patients had bilateral lower limb deformities. In 14 the proximal tibia was involved causing genu varum in 12 cases and genu valgum in two cases. Seven distal tibia deformities all resulted in varus deformity. In all cases, the fibula was spared.

Discussion In this series involvement of the tibial physeal growth plates was frequently asymmetric and with two exceptions resulted in a varus deformity. The medial and anterior proximal tibial physis seems particularly susceptible to the sequelae of meningococcal septicaemia whereas the fibula physeal plates were always spared. These observations confirm the work of other authors and this characteristic pattern of involvement is likely to reflect the vascular anatomy of the physeal plates. The fibula may be protected from damage because of the nature of its blood supply. Modern limb reconstruction techniques, particularly the Spatial frame now permit correction of these complex and difficult deformities.

FREE PAPERS
SESSION 3

MODERATOR: JONATHAN MCGREGOR-RILEY

COST OF PHYSIOTHERAPY TREATMENT FOR ILLIZAROV FRAMES

E Barron, R Rambani, HK Sharma
Department of Orthopaedics, Hull Royal Infirmary Hull

The present study was conducted to evaluate the cost of physiotherapy both for inpatient and outpatient services. Significant physiotherapy resources are required to rehabilitate patients with an Ilizarov or Taylor Spatial Frame (TSF). Within Hull and East Yorkshire Hospitals NHS Trust Physiotherapy department the average number of outpatient treatment sessions per routine patient is 6. In comparison, the average number of treatment sessions required for a patient with an ilizarov (or TSF) is 24 for a trauma patient and 33 for a patient undergoing an elective procedure.

Seventy three (73) patients received physiotherapy treatment with an Ilizarov frame or a Taylor spatial frame between April 2008 and April 2010. Physiotherapy input was recorded (in minutes) for the patients identified. This included treatment received as an inpatient as well as an outpatient (if the patient received their treatment within Hull and East Yorkshire NHS trust).

Data collection was divided into either trauma or elective procedure for analytical purposes. The average cost of physiotherapy treatment to Hull and East Yorkshire Hospitals NHS Trust for an inpatient with an ilizarov frame is £121.82 per case (trauma) and £133.15 per case (elective).

The average cost of physiotherapy treatment to Hull and East Yorkshire Hospitals NHS Trust for an outpatient for a trauma case was calculated as £404.65 and £521.41 for an average elective case. This is in comparison to a routine patient costing the service £60.29 (when treated by a Band 7 physiotherapist). The present study gives valuable data for future business planning and assistance with the setting of local or national tariffs for the treatment of this patient group.

FIXATION AND SLIPPAGE OF KIRSHNER WIRES IN ILIZAROV EXTERNAL FIXATORS

Mr Michalis Zenios, Farshid Zamani, SO Oyadiji
School of mechanical, aerospace and civil engineering. University of Manchester.

Purpose of the study: The aim of this mechanical study was to investigate the ability of cannulated fixation bolts to stop wire slippage in Ilizarov circular external fixators.

Methods and Results: Three types of cannulated fixation bolts (Smith and Nephew, Orthofix and one designed by the authors) were tested on Ilizarov rings to compare their performance. Three levels of bolt torques were applied and the wires were pulled to measure the load at which the wire will start to slip or fail. It was revealed that the initial resistance to slippage is due to plastic deformation of the wire under the clamp and is in fact governed by the size of this deformation. The slippage was found to occur in a slip/stick fashion, as the plastic deformation was propagated along the wire.

Conclusion: The more the plastic deformation caused by the bolt on the wire the higher the initial resistance to loading.

TELESURVEILLANCE OF CIRCULAR FRAME PIN-SITES: A ONE-YEAR EXPERIENCE AT A SPECIALIST UNIT

S K Khan, A Abraham

Leicester Royal Infirmary, Infirmary Square Leicester LE1 5WW

Statement of purpose Circular frames treatment for limb reconstruction involves repeated follow up visits, and a substantial number of these appointments are for pin site review only, and incur a significant cost to the NHS. We advocate 'Telemedicine' as a logistically and economically viable option for routine post-operative review of pin-sites.

Methods and results The senior author performs fifty to sixty frame circular frame treatments in adults for trauma every year. For the past 12 months, we have been encouraging our frame patients to take photographs of their pin-sites when they do their weekly dressing changes. This is done with digital cameras by the patients themselves, and the images are then emailed to the senior author on his work email address, and get replied to by the next day. If the images are a cause for concern, further steps are initiated (Images 1 and 2 demonstrate pin-sites before and after a course of antibiotics, started because the first image was a cause for concern). This arrangement is for pin-site reviews only. This method has been used for the post-op pin site review of five patients with circular frames.

Conclusion We have so far experienced a high level of patient satisfaction and significant benefits with pin-site telesurveillance in our limited number of patients, and plan to incorporate this as a formal protocol in our practice.

TRANSVERSE BONE TRANSPORT USING ILIZAROV PRINCIPLES

Mohamed M. Fadel and Gamal A. Hosny

Department of Orthopedic Surgery, El-Minia University, and Benha University; Egypt

Abstract The specific methods of skeletal reconstruction of massive bone loss remains a topic of controversy. The problem increased in case of massive bone loss, extensive soft tissue scar, vascular compromise, and short tibial remnants.

Aim of the work: We evaluate the use of fibula in association of Ilizarov external fixator in management of massive post traumatic bone loss of tibial shaft.

Materials and methods Between December 1999 and 2004, we treated 8 adult patients with bone loss 10 cm and more. The indication was massive bone loss, extensive soft tissue scar, vascular compromise, and short tibial remnants. Whole fibula was used in 6 conditions and partial fibula in 2. The average age was 30.5 years (range: 25:51). The fibulas were prepared for transfer either as a whole or partially transfer. Ilizarov device was applied with a special construct for each condition accordingly. Free latismus dorsi was applied in 1 patient, and fasciocutaneous flaps in 2. Four patients with whole fibula transfer continued to wear orthosis for outdoor activities.

Results The mean follow-up period was 40 months (range: 24:96) after healing. All fractures healed between 8 and 24 months.

Conclusion We concluded that the Ilizarov external fixator is effective in management of massive post traumatic bone loss of tibial shaft. It provides advantages of compensation of bone defects, length, and early rehabilitation. It has the disadvantages of long healing time, long orthotic support. Its advantages are clear in case of massive bone loss, extensive soft tissue scar, vascular compromise, and short tibial remnants.

ANKLE / HINDFOOT SALVAGE ARTHRODESIS USING EXTERNAL FIXATION

P Moras, J A Long, A J L Jowett, S L Hodgkinson, I F N Lasrado, C J Hand.
Queen Alexandra Hospital, Portsmouth

Purpose of the study: We report on the clinical, radiographic and functional outcomes after salvage arthrodesis for complex ankle and hindfoot problems - the Portsmouth experience with the Ilizarov ring fixator.

Methods and results: We report on 10 patients who underwent ankle and hindfoot (tibio-calcaneal) arthrodeses using an Ilizarov ring fixator between 2006 and 2010. The indications included failed fusion after primary arthrodesis, sepsis complicating internal fixation of fractures, talar avascular necrosis and failed total ankle arthroplasty (TAR). All patients had undergone multiple previous surgeries which had failed. There were 7 males and 3 females in this group. Average age of the patients was 60 (47 years – 77 years) Mean follow up was 32 months (6 – 56 months) BMP 2 (Inductos) was used in three cases. The procedure was combined with a proximal corticotomy and lengthening in 2 patients who had undergone a talectomy and tibio-calcaneal fusion. There were no major complications apart from minor pin site infections requiring oral antibiotics. There were no deep infections, thrombo-embolic issues, CRPS, or functional problems on account of limb shortening. Patients were assessed clinically, radiologically and using functional outcome scores EQ50 and AOFAS. Solid arthrodesis was achieved in all but one patient who was subsequently revised with a hindfoot nail. All patients were satisfied with their overall improvement in pain and function.

Conclusion: We conclude that this is an effective salvage technique for complex ankle and hindfoot problems in patients with impaired healing potential, insufficient bone stock and progressive deformity.

SIMULTANEOUS MANAGEMENT OF HAND TO KNEE AND SHORTENING PROBLEMS IN POLIOMYELITIS.

A S Allam , M.D.
Benha University, Egypt.

***Background:** In poliomyelitis; hand to knee gait is the sum of quadriceps weakness and fixed knee flexion deformity. Limb shortening is another added problem. Usually, each problem is attacked separately; with variable end results and complication rates for each procedure.

***Patients and methods:** 22 patients (16 – 46 y.); with poliomyelitis with hand to knee gait due to fixed knee flexion deformity of mild to moderate degree ($10 - 40^{\circ}$); and limb shortening of 4.5 – 9.5 cm., were managed simultaneously by a single operation. A distal femoral metaphyseal anterior closing wedge (recurvatum) corrective osteotomy was done to treat acutely the fixed knee flexion deformity (and subsequently hand to knee gait). A modified Wagner or Orthofix frame was applied as a mono-plane mono-axial lengthening device to stabilize the osteotomy and to lengthen the short limb. Lengthening was started in all cases two weeks post-operatively.

***Results:** All cases showed full correction of the deformity with elimination of the hand to knee gait problem and all showed - the desired - limb length equalization. The femora were lengthened to an average of 6.4 cm. (= 21 % of original femoral bone length) , range of lengthening was : 4 - 9 cm. (= 11 – 26 %). The average healing index was 37 days per centimeter (with a range of 31 to 53 days per centimeter.)

***Conclusion:** Simultaneous management of hand to knee and limb shortening could be achieved by a single osteotomy which is used to extend the knee acutely and for distraction two weeks later using a mono-lateral frame. Results were good, complications were few and accepted and the procedure is well tolerated by the patients.

FRIDAY, 28th January 2011
FREE PAPERS

SESSION 1, BEST PAPER SECTION
MODERATOR: GERAINT DAVIES

SHEFFIELD TELESCOPING ROD VERSUS RUSH PIN IN THE TREATMENT OF OSTEOGENESIS IMPERFECTA

Gamal EL-ADL, Mohamed A. KHALIL, Ahmed ENAN, Mohamed F. MOSTAFA,
Mohamed R. EL-LAKKANY
From Mansoura University Hospital, Mansoura, Egypt

Aim: A retrospective study was undertaken to evaluate and compare the results of telescoping (group I) versus non telescoping rods (group II) in the treatment of osteogenesis imperfecta.

Materials and Methods: Thirty-three lower limb segments in ten patients were studied (14 segments in group I and 19 segments in group II). The surgical techniques of Sofield and Miller (1959) and Lang-Stevenson and Sharrard (1984) for rod insertion were used. All cases were assessed clinically regarding mobility status, growth and limb-length, refracture, and infection. They were also assessed radiologically regarding rod migration, bone outgrowing the rod, incorrect T-piece placement, breakage and bending of rods.

Results: The average duration of follow-up was 86.2 months (range: 6 to 8 years). Mobility status and bone growth were better in group I than in group II patients. The overall implant related complication rate was 28.6% in group I in comparison to 68.4% in group II. Rod migration was twice more common in group II than in group I. Bone outgrowing the rod and breakage of rods with fracture was seen in group II only. The three-year survival rate for telescoping rods was 92.9% in contrast to 68.4% for non telescoping rods. The reoperation rate was 7.2% in group I and 31.6% in group II.

Conclusions: From this comparative study it was clear that the results were significantly better after Sheffield rods with regard to mobility status, longevity of the rod, and the frequency of complications requiring reoperations. Also most of the complications were related to the technique of rod insertion and the type of rod.

REDISLOCATION AND THE COMPUTERISED TOMOGRAPHY EVALUATION OF DEVELOPMENTAL DYSPLASIA OF THE HIP

A P Cooper, M J Flowers
Sheffield Children's Hospital

Aims The purpose of this study was to calculate the dislocation rate following open or closed reduction for developmental dysplasia of the hip (DDH) in our unit. In addition we evaluated the posterior neck line as a method of determining hip relocation and assessed the morphology of the dysplastic acetabulum on single slice CT scan.

Method We retrospectively assessed all patients operated on for either open or closed reduction for DDH between August 2007 and August 2009 and evaluated their notes, CT scans and radiographs. The immediate post-operative dislocation rate was calculated, as was the subsequent re-dislocation rate and late subluxation rate. The acetabular morphology was assessed to determine whether the acetabulae were "S" shaped or "C" shaped. A novel method for confirming hip reduction was also appraised.

Results Seventy-five hips were operated on during the study period. The immediate post-operative dislocation rate was 9.3%. There were no subsequent dislocations in any of the patients in whom CT scans had confirmed adequate initial reduction. Two patients went on to develop late subluxation. 98.6% of dysplastic acetabulae displayed an S shaped acetabulum and 1 hip had a virtually flat acetabulum. The posterior neck line test for dislocation had an 85.7% sensitivity and 96.9% specificity.

Conclusions Immediate post-operative CT scan of the hip is a useful investigation following reduction of the hip for DDH. If it can be established that the hip is reduced on the scan it is unlikely to re-dislocate. The S shape of the acetabulum in DDH is consistently present and is a marker of the dysplastic posterior acetabular wall. The posterior neck line is a reliable measure of hip reduction.

MANAGEMENT OF THE SEQUELAE OF OLD SEPTIC HIP OF INFANCY

ABDELSALAM MOHAMMED HEFNY, M.D.
AHMAD ALTONESY ABDELSAMIE, M.D.
AHMAD HASHIM AMIN, M.D.
Faculty of Medicine Zagazig University. EGYPT

Introduction

Septic arthritis of the hip in the newborn baby can result in severe long term sequelae in the form of dislocation of the hip, loss of movement and growth disturbance with leg length discrepancy. Reconstructive procedures for this difficult problem have not been satisfactory

Patient and methods

This series comprises eight patients with septic hip sequelae. All of them had old septic hip and leg length discrepancy ranging from 4 cm to 15 cm. all underwent hip stabilization by pelvic support osteotomy and simultaneous limb lengthening and angular deformities correction using the Ilizarov frame. The age at the operation range from 8 years to 19 years, with an average follow up 4 years.

Results

The average of limb lengthening gained was 9cm. All hips remain stable and loss of the range of hip and knee motion was not significant. Other complications include pin tract infection one delayed consolidation of callus and one fracture of callus.

Conclusion

The Ilizarov hip reconstruction is a good option for the treatment of the late sequelae of infantile hip infection in adolescents. It should be considered a promising choice for the management of late sequelae of infantile hip infection.

CLOSED REDUCTION AND OPEN SOFT TISSUE RELEASE FOR BILATERAL HIP DISLOCATIONS.

AG de Gheldere MD , A Hashemi-Nejad FRCS, P Calder FRCS, S Tennant FRCS, DM Eastwood FRCS
The Royal National Orthopaedic Hospital, Stanmore, London

Purpose: To document the success rate of closed reduction and soft tissue release in the treatment of bilateral true dislocation in developmental dysplasia of the hip (DDH).

Methods: Case-note review of 22 children (44 hips) with idiopathic bilateral hip dislocation referred to a tertiary centre before walking age. The management protocol was as follows:

1. Examination under general anaesthesia, arthrogram, closed reduction and appropriate soft tissue release (adductors/psoas), application of a 'frog' cast.
2. CT scan at 2 weeks to confirm reduction.
3. Change of cast and arthrogram at 6 weeks to confirm improving position and stability.
4. Cast removal at 12 weeks, and application of an abduction brace for 6 weeks. Treatment failure could occur on day 1 (failure of reduction), at week 2 (failure to maintain reduction), at week 6, or after cast removal.

Results: Median age at presentation was 3.8m (2w-7.5m). 19/22 were girls. 7 had a caesarean section for breech presentation, 16/22 had had prior Pavlik harness treatment. All hips were Tonnis 2 or more. Mean age at surgery was 7 months (range 3-12m). 9/44 hips failed on day 1. 13/44 hips failed at 2 weeks. 1/44 hip failed at 6 weeks. 8/22 patients had bilateral failure. 7/22 patients maintained a unilateral hip reduction and 7/22 patients maintained a bilateral reduction after treatment. Mean follow-up was 25m (range 6-71m). 1 patient has bilateral AVN. Successful results were not associated with presentation, previous treatment given, the level of dislocation (Tonnis) or patient age at time of treatment.

Conclusion: Following a successful initial reduction, this protocol failed to maintain reduction in 13/35 (40%) hips at 2 weeks: significantly worse than our presented results for unilateral dislocation.

Significance: With our current protocol, the percentage chance of reducing at least one of bilateral idiopathic dislocated hips is 64% (14/22) but parents should be told that there is only a 1:3 chance of a successful outcome for both hips following closed reduction.

A CHANGING PATTERN OF FEMORAL FRACTURES IN OSTEOGENESIS IMPERFECTA WITH PROLONGED USE OF BISPHOSPHONATES

N Nicolaou, M Padman, Y Agrawal, MJ Bell, JA Fernandes
SHEFFIELD CHILDREN'S HOSPITAL

PURPOSE OF THE STUDY- TO ASSESS IF PROLONGED USE OF BISPHOSPHONATES IN OSTEOGENESIS IMPERFECTA ALTERS THE PATTERN OF FEMORAL FRACTURES

Osteogenesis Imperfecta (OI) has been treated with Bisphosphonates for many years with some clear clinical benefits. In adult cohorts there are reports of a new pattern of atraumatic subtrochanteric fractures seen with Bisphosphonate treatment.

SUMMARY OF METHODS

This study assesses the location of femoral fractures in a cohort of 176 OI patients treated with Bisphosphonates over a two year period and compares it to a historical control group of 45 managed prior to the advent of this specific treatment.

SUMMARY OF RESULTS

A review of the radiological digital archive identified 16 femoral fractures in this time period in the Bisphosphonate treated group. All but 2 were within 5cm of the lesser trochanter, and 50% within 3cm. In comparison, the historical group, composed of 26 femoral fractures had a more widespread fracture pattern with the most frequent location being the mid-diaphysis. Many of the sub-trochanteric fractures in the treatment group occurred with minimal trauma, and in some cases without any injury.

CONCLUSION It appears that concerns in the adult osteoporotic population treated with Bisphosphonates are mirrored in Osteogenesis Imperfecta. It is possible that the high bending moments in the proximal femur together with altered mechanical properties of cortical bone secondary to the use of this group of drugs, mediated by abnormal osteoclast and osteoblast function, increase the risk of this type of injury and warrants further investigation.

EXPERIENCE AND COMPLICATIONS ASSOCIATED WITH THE FASSIER-DUVAL TELESCOPING NAILING SYSTEM

D M Wright, J Sampath,, S N Nayagam, A Bass
Alder Hey Children's Hospital, Liverpool, UK

The aim of this retrospective study was to review the outcome of patients treated with Fassier-Duval (FD) rods and highlight some of the complications found during treatment.

Between April 2006 and August 2010 we inserted 24 FD rods in 13 patients. 17 rods for osteogenesis imperfecta (OI), 2 for fractures and deformity associated with cerebral palsy, 1 for fracture associated with muscular dystrophy, 1 for fibrous dysplasia and 3 for centralisation of single bone forearms.

In the upper limb one patient required revision for proximal migration of the male component and another patient is waiting for revision for the same problem.

In the lower limb, a tibial nail was revised because of proximal migration of the male component. A femoral nail was adjusted because of loss of the proximal fixation. One of the OI patients fell, fractured the femur and bent a femoral nail. This awaits revision at a later date. A second OI patient fell on 2 separate occasions bending both a tibial and a femoral nail respectively. These were both revised to trigon intramedullary nails.

In all the other cases there were no complications.

In summary the Fassier Duval system provides a versatile way of providing intramedullary stabilisation for growing bones through a single entry point. However in our experience we have a 33% complication rate most notably bending of the rods. We advocate careful patient selection and using as high a diameter nail as is feasible.

FREE PAPERS
SESSION 2
MODERATOR: MARK J FLOWERS

A REVIEW OF THE ROLE OF EXTERNAL FIXATORS IN PAEDIATRIC TRAUMA AT THE ROYAL LONDON HOSPITAL

GILLANI S, HUMPHREY JA, BARRY M.

Barts and the London NHS Trust, Trauma and Orthopaedic Department

Purpose: A review of the role of external fixators in paediatric trauma at The Royal London, Trauma and Orthopaedic Department.

Methods: Retrospective study between 2004 and 2010 reviewing traumatic bone injuries that required initial management with an external fixator. Information was collected through the patients' medical documents and radiographs.

Results: In total twenty-seven patients (15 male:12 female, mean age 11, age range 7-15) were initially treated with external fixators over the six year period. The injured bones included 18 tibias, 5 femurs, 2 humeri, 2 radius/ulna, 2 phalanges and 1 wrist. Three patients had two fractures requiring external fixators. Four patients had associated head injuries. Indications included twenty –one open fractures (3 Gustilo type 2, 6 Gustilo type 3A, 12 Gustilo type 3B), seven closed fractures in poly-trauma patients and two closed severely comminuted fractures. Ten fractures were treated with the external fixator as the definitive treatment, fourteen had application of cast following removal of the external fixator and six were converted to internal fixation. Twenty-eight Linear frames were applied (23 Hoffman IIs, 5 Compact Hoffmans) and two circular frames. Mean duration of frame stabilisation was 8 weeks (range 1-16 weeks). Complications included 2 pin site infections successfully treated with antibiotics, 2 patients with hypertrophic scars, 2 leg length discrepancies secondary to bone loss, 2 patients had delayed union and 2 patients had a lower limb deformity requiring intervention, one for adjustment of frame and the other for correction osteotomy with circular frame.

Conclusion: The use of external fixators has an important role to play in the management of open fractures and poly-trauma paediatric patients.

COMPLEX FOOT DEFORMITIES IN CHILDREN AND TAYLOR SPATIAL FRAME CORRECTION

C J Edwards, E D Gent, R Asp, M G Uglow
Department of Paediatric Orthopaedics,
Southampton University Hospitals Trust,
Tremona Road, Southampton SO16 6YD

Statement of Purpose Our experience with Taylor Spatial Frame correction of complex foot deformities in children.

Persistent foot deformity in congenital talipes equinovarus is a challenge. Open surgery is associated with complications including difficulty in achieving acute corrections in stiff, scarred feet. Gradual correction using the Ilizarov circular frame has been described as an alternative and we present the experience using a computer assisted hexapod gradual frame correction with the Taylor Spatial Frame (TSF).

A retrospective audit of sequential patients treated by TSF was performed.

Technique, outcome, complications and key learning points were recorded.

21 paediatric patients underwent 27 treatments with a Taylor Spatial frame for complex foot deformity correction. Average age 11 years with majority diagnosis of congenital talipes equinovarus. The deformities severity meant acute correction would result in either neurovascular or soft tissue compromise.

Plantigrade feet with good function was achieved in 22 feet. 3 feet were deemed as failures. 2 feet have residual deformity but acceptable function. According to Paley's classification, there were 4 complications, 7 obstacles and 35 difficulties (pin tract infection and pain management). Complications did contribute to poorer outcomes. The key learning points were: protection of the ankle joint and distal tibial physis; staged osteotomy reduces swelling and complication rates; and consideration of further procedures at frame removal is important. Finally a thorough preoperative counselling programme should be instituted and patients warned of the time commitment and high difficulty rates associated with treatment. Managing patient expectation with goals is as important as meticulous surgery.

Although complication rates were high, the majority of treatment goals were met, therefore the TSF is valid in the treatment of complex deformities in the foot. Most patients with severe deformity can achieve a plantigrade functional foot but residual stiffness and need for minor orthotics is almost universal.

CONGENITAL PSEUDARTHROSIS OF THE TIBIA: A SINGLE SURGEON SERIES OF 19 CHILDREN

A Ghassemi, N Nicolaou, R A Hill
Great Ormond Street Hospital for Children NHS Trust

PURPOSE To report the experience and evolution of treatment of Congenital Pseudarthrosis of the Tibia in a single surgeon, consecutive series of 19 patients

METHODS A retrospective case series review, with radiological assessment and functional outcome scores including the Activity Scale for Kids (ASK) and the Oxford Ankle Foot Questionnaire (OAFQ) Child & Teenager version. Patients were classified as per Boyd & Andersen. Alteration in the Tibial mechanical axis was compared pre-treatment and at last review.

RESULTS The average follow up from presentation was 6.3 years, 7 patients had reached skeletal maturity. Union was obtained in 79% at the time of review with a mean time to union of an established pseudarthrosis of 15.2 months. 9 of 19 had an established diagnosis of Neurofibromatosis. 8 had a frank pseudarthrosis at presentation, 2 of which were present at birth. There were 3 re-fractures following treatment. One of the 19 required amputation after failed surgical treatment. Each patient had an average of 2.4 surgical procedures. 14 patients had either fixed or elongating rods, 10 had Ilizarov treatment. 2 have outstanding surgery planned.

CONCLUSIONS A philosophy of treatment has evolved which produces acceptable results. Splintage is used for antero-lateral bowing with corrective osteotomies and rodding, without extensive bone or periosteal resection, for significant or progressive deformity or fracture. Ilizarov treatment is used for recalcitrant cases over the age of 6 years. The technique has evolved over time to include bone graft wraps and the use of Bone Morphogenic protein in combination with the Ilizarov technique. Patients have below population and age matched average scores for both the ASK and OAFQ.

INTRAOSSUEOUS ACCESS AND AMPUTATION

CC Taylor, NMP Clarke
Southampton University Hospital

Purpose: We describe two recent cases of intraosseous (IO) access resulting in amputation in critically ill infants and make contemporary recommendations on the safe practice of this technique.

Methods/results: This is a retrospective case series of two children transferred from peripheral hospitals to our unit. One child (5 months) was resuscitated after cardiorespiratory decompensation due to diaphragmatic hernia. The other child (18 months) deteriorated during presentation with purpura fulminans two days after a scald injury. Both children underwent emergent bilateral tibial IO access using power driven needle systems. Initial resuscitation included large volumes of 0.9% normal saline. One child received doses of adrenaline and 8.4% sodium bicarbonate, whole blood and an initial dopamine infusion; the other received 8.4% sodium bicarbonate, 10% calcium gluconate and whole blood. Total infused volumes were 400mL and 730 ml respectively.

Progressive lower limb tension became evident in both children after 12 hours; bilateral posterior tibial fractures were noted in one child. Ultimately, both children underwent surgical fasciotomy, but extensive necrosis necessitated unilateral below knee amputation at days 12 and 13 respectively.

Conclusions: Fluid extravasation has been implicated in complicating IO access, particularly with high volume or prolonged infusions. Other potentiating factors include inaccurate needle placement, needle dislodgement during transfer and repeated infusion of irritant solutions. All of these contributed to irreversible lower limb ischaemia in these two cases. Adherence to the principles of careful needle placement, splinting, limited length of infusion and repeated monitoring of the limb will help avoid this devastating complication.

A CASE SERIES REVIEW OF THE ORTHOPAEDIC PROBLEMS ASSOCIATED WITH PSEUDOACHONDROPLASIA

N Siddiqui FRCS, O Malaga-Shaw MD, D M Eastwood FRCS
The Royal National Orthopaedic Hospital and Great Ormond St Hospital, London

Purpose: To define the orthopaedic problems associated with pseudoachondroplasia (PSACH) and their functional impact.

Methods: We reviewed the medical records of 12 consecutive patients presenting to our unit. Radiographic analysis of deformity included assessment of mechanical axis and dysplasia at hip, knee and ankle measured by acetabular index (AI), Reimer's migration percentage (MP), neck-shaft angle, distal lateral femoral (aDFLA) and proximal (mMPTA) and distal tibial angles.

The paediatric/adolescent PODCI questionnaires and the SF36 were used to assess quality of life issues.

Results: 12 patients (9 female) were reviewed at median age 18yrs (range 12-43yrs). Most symptoms related to walking tolerance, joint discomfort and deformity: 9 patients had genu varum, 7 tibial torsion, 2 patella instability and 3 significant low back pain.

All patients had hip dysplasia. 10 had medial displacement of the mechanical axis, with a mean mDFLA 105 deg (88 -128) and mMPTA 75deg (51-90).

2 patients have been treated only with growth hormone; 10 patients have undergone a total of 9 distal femoral, 19 proximal tibial and 2 supramalleolar osteotomies. 6 procedures were performed using an external fixator. 7 limb segments have been treated by guided growth and in all these cases alignment has improved. One patient has had bilateral hip arthroplasties (age 29), a second patient has had bilateral patellectomies. These 10 patients have undergone a mean 3.8 operative procedures on a mean 2.4 occasions.

Patients scored less well than their peer groups in all domains of the PODCI assessment. All have maintained some independent mobility.

Conclusions: PSACH is a severe skeletal dysplasia with deformity at all levels of the lower limb affecting patient satisfaction and quality of life. Knee deformities are those which most frequently require surgical intervention.

Significance: The genetic defect in PSACH differs from that in achondroplasia, joint degeneration is more common and maintenance of limb alignment is essential.

CYST FLUID AND STEM CELLS:
WHY UNICAMERAL BONE CYSTS ARE SO HARD TO TREAT

A Aarvold, JO Smith, CJ Edwards, ER Tayton, ED Gent, ROC Oreffo
Bone & Joint Research Group, University of Southampton Medical School
& Dept of Paediatric Orthopaedics, Southampton General Hospital

Background Unicameral bone cysts (UBCs) are difficult to treat and have a high recurrence rate. Their pathogenesis is unknown making targeted therapies difficult. Attributed causes include venous and interstitial fluid obstruction, oxygen free radicals, lysosomal enzymes, prostaglandins and genetic factors. Skeletal stem cells (SSCs) are osteoblast precursors critical to bone formation and cyst fluid may influence their growth, however the association between SSCs and cyst fluid has never been investigated.

Aim To investigate the effect of UBC fluid on SSC growth.

Methods Fluid was aspirated from a UBC in the proximal femur of a nine year old boy and centrifuged to isolate the acellular supernatant. SSCs were harvested from bone marrow of a haematologically normal adult and cultured with graded concentrations of cyst fluid in culture media (0,10,25,50%). Cell growth was assessed by alkaline phosphatase staining, and cytokine levels in the fluid were measured.

Results High levels of cytokines known to be chemo-attractive for cells of the of macrophage-monocyte lineage were found, including Macrophage Chemotactic Protein-1 (1853pg/ml), Monokine Induced by γ -interferon (656pg/ml), Macrophage Inflammatory Protein (MIP)-1 α (401pg/ml) and MIP-1 β (34pg/ml) suggesting a role of osteoclasts in UBC pathogenesis. Furthermore, SSC growth *in vitro* was reduced in cyst fluid in a concentration dependent manner.

Conclusion This is the first time altered SSC and osteoprogenitor function has been associated with the fluid of a UBC. A negative effect on osteogenesis was demonstrated, the precise mechanisms of which are under investigation, and macrophage-monocyte chemokines suggest high osteoclast activity. This study has indicated a role of the cyst fluid in limiting osteogenesis and bone turnover, which may explain the high failure rate for current interventions. More patients are needed to validate these findings.

CONSISTENCY IN RATING CRITERIA FOR THE DIAGNOSIS OF DEVELOPMENTAL DYSPLASIA OF THE HIP AMONG MEMBERS OF **BRITISH SOCIETY FOR CHILDREN'S ORTHOPAEDIC SURGERY (BSCOS)**

A Roposch, LQ Liu, D Kulaveerasingam
Great Ormond Street Hospital for Children, London

Purpose of the study: To determine the consistency with which specialist orthopaedic surgeons rate the importance of criteria for the diagnosis of DDH which had previously been generated in a BSCOS and EPOS multi national study.

Methods: 163 members of BSCOS received a questionnaire containing 37 criteria that, in a previous study, had been found to be important for the diagnosis of DDH in infants under 8 weeks. A visual analogue scale was used to rate the importance of each criterion in the diagnosis of DDH. We determined the consistency using the intra-class correlation coefficient (values > .80 are anticipated). Analyses were preformed for all members of BSCOS and for geographic regions.

Results: The response rate was 61%. Cronbach's α was .98 indicating that the pattern of the data observed was stable. The overall consistency was poor for all 37 criteria (ICC = .39 [95% CI .29, .52]). Surgeons were least consistent about criteria related to ultrasound (ICC = .25). The consistency for criteria related to patient characteristics (ICC = .40) and x-ray (ICC= .32) was better. Surgeons were most consistent (ICC = .51) about criteria related to clinical examination. Analyses based on regions of England, Scotland and Wales improved consistency by 25% (best ICC = .47) with West Midland, Yorkshire and Scotland rating top three.

Conclusion: Surgeons' opinion about the importance of criteria for the diagnosis of DDH varies substantially across the UK. This study suggests a need to develop widely accepted criteria for the diagnosis of DDH that can be applied with sufficient degree of consistency among surgeons. Reducing inconsistency in this area should improve diagnosis and treatment.

BILATERAL CDH OUTCOMES AND COMPLICATIONS ANALYSIS

V Goriainov, CG Gibson, NMP Clarke
Southampton General Hospital.

AIMS We present a retrospective study of bilateral CDH. We analysed the correlation of complications to the confounding factors.

MATERIAL AND METHODS We reviewed all bilateral CDH patients treated by the same surgeon at SGH between 1988-2006. The patient recruitment was carried out as follows:

- 1) Group A – failed Pavlik harness;
- 2) Group B – late presentations not treated in Pavlik harness.

RESULTS The series included 50 patients (5 males; 45 females). The average age at presentation was 21 weeks (1-160). The average age at reduction was 15 months (4-45). The average follow-up was 6.7 years (4-15).

4 hips required revision due to loss of reduction. The number of surgical interventions throughout the treatment course ranged 4-12 (average – 7.3).

AVN occurred in 17 hips (17%). Previous Pavlik harness treatment, CR and higher height of dislocation (HD) were associated with increased the rate of AVN.

42 pelvic (PO) and 12 femoral (FO) osteotomies (54%) were performed. CR and greater HD increased the pelvic osteotomy rate, while Pavlik harness treatment failure did not affect it.

The mean AI demonstrated a gradual decline following reduction. While there was no difference between OR vs CR, and Group A vs B, the $HD \geq 3$ was associated with a significant acetabular development delay when compared to $HD \leq 2$.

CONCLUSIONS Despite the complexity of CDH cases, it is possible to achieve an acceptable level of inevitable complication (AVN – 17%, PO – 42%, FO – 12%, revision reduction – 4%). The rate of AVN was independently negatively affected by CR and prolonged immobilisation. Only the hips with initial HD of ≤ 2 had their acetabular index return to normal ($< 21^\circ$) before the age of 4 years.

This is the first comprehensive analysis of bilateral CDH cases, emphasising the difficulty of treatment of this condition and providing the foundation for an outcomes-predicting system.

CONGENITAL RADIOULNAR SYNOSTOSIS; A NEW OPERATIVE TECHNIQUE FOR OBTAINING FUNCTIONAL SUPINATION – PRONATION RANGE, A SERIES OF ELEVEN CASES.

AS Allam , M.D. ,
Benha University , Egypt.

* Background: CRUS is difficult to treat. Many techniques have been tried in an effort to restore forearm rotation; however, they have not been successful. It is inadvisable by many authors to perform any operation with the hope of obtaining probation and suspension.

* Patients and Methods: Eleven children; 3 - 8 years old with CRUS, Wilkie type I , with fixed full probation deformity were managed by the new ALLAM'S OPERATION which is a one stage intervention including separation of the bony fusion, special cementation technique of the lunar (or radial) side of the osteotomy , double osteotomy of the radius and a single osteotomy of the ulna (all of the 3 osteotomies were done percutaneously) with intramedullary K. wire fixation of osteotomies at the mid-prone position and above elbow cast application for 6 weeks.

* Results: Excellent significant functional range of forearm rotation was obtained with no significant complications after a follow-up period of 3 – 4 y. (average: 3.2 m).

* Summary: The new ALLAM'S OPERATION is a one stage intervention for CRUS, (Wilkie type I , with fixed full pronation deformity) with significant obtained active functional range of forearm rotation with no significant complications after an average follow-up period of more than 3 years.

LEGG-CALVE-PERTHES: INTEROBSERVER AND INTRAOBSERVER RELIABILITY OF THE MODIFIED HERING LATERAL PILLAR CLASSIFICATION

R.A.Rajan, J.Chandrasenan, J.Metcalf and C Konstantoulakis.
Derby Children's Hospital and Sheffield Children's Hospital.

The purpose of our study was to independently assess the modified Herring lateral pillar classification.

Methods and results: 35 standardized true antero-posterior radiographs of children in various stages of fragmentation were independently assessed by 6 senior observers on 2 separate occasions (6 weeks apart). Kappa analysis was used to assess the inter and intraobserver agreement between observations made. Intraobserver analysis revealed at best only moderate agreement for two observers. 3 observers showed fair consistency, whilst 1 remaining observer showed poor consistency between repeated observations ($p < 0.01$). The highest scores for interobserver agreement varying between moderate to good could only be established between 2 observers. For the remaining observers results were just fair ($p < 0.01$).

Conclusion: This study highlights the lack of agreement between senior clinicians when applying the modified LPC. This clearly has clinical implications. To our knowledge this is the first time the modified lateral pillar classification has been independently tested for its reproducibility by a specialist paediatric orthopaedic unit.

CONSIDERATION OF THE OBLIQUE PLANE DEFORMITY IN SLIPPED UPPER FEMORAL EPIPHYSIS

CJ Geddis, F Ali, JA Fernandes, S Madan.
Sheffield Childrens Hospital, UK.

The purpose of this study was to determine the oblique plane deformity in slipped upper femoral epiphysis.

A retrospective radiographic review was undertaken in patients admitted with a slipped upper femoral epiphysis between March 2008 and October 2010. Patients in whom a CT scan had been performed in addition to plain radiographs were assessed further. Angular deformity in the coronal and sagittal planes were measured by the angle formed between the femoral neck and a line perpendicular to the physis on the AP pelvic radiograph and the axial CT scan respectively. The magnitude and direction of the resultant deformity was defined in the oblique plane. Additional demographic data (gender, age, side, procedure and complications) was collected. Seven girls, average age of 12 (range 10 – 13) and 6 boys, average age of 13 (range 10 – 15) were identified. The slip was bilateral in 2, left sided in 6 and right sided in 5 cases. Two patients were pinned in situ, 8 had surgical dislocation performed to facilitate reduction prior to pinning and 3 patients had secondary procedures performed following in situ pinning. The average angulation in the oblique posteroinferior plane (25 degrees) was less than in the coronal (30 degrees) and the sagittal planes (62 degrees). The average magnitude was 67mm (range 31 – 88). CT is useful adjunct particularly when a frog legged lateral view is not possible because of pain or the fear of further displacement. Determination of the deformity in the oblique plane may aid in positioning of the screw during in situ pinning and may be helpful in identifying patients in whom pinning maybe difficult.



**The First Combined Meeting of
British Limb Reconstruction Society
&
British Society for Children's Orthopaedic Surgery**



26, 27 & 28 January, 2011

We would like to take this opportunity to thank the following people and organisations for contributing to our first combined meeting.

~ Louise O'Carroll FitzPatrick, ethos conference consultants, www.ethosconference.co.uk

~ Carol's Catering Services, www.carolscateringsheffield.co.uk

~ Northern General Hospital, Sheffield

~ Lesley Izzard, Medical Education Centre, Northern General Hospital

~ Stuart Barraclough & Edward Nicholson, Xerox

~ Baldwins Omega, www.baldwinsomega.com

~ Mayfair Coaches, 01142758885

~ **Gold Sponsors – Whole Event**

Boehringer-Ingelheim
Medtronic
Orthofix
OrthoSolutions
Smith & Nephew

Gold Sponsors – BSCOS only

Ipsen

Silver Sponsors – Whole Event

OrthoPediatrics
Platts & Nisbett
Stryker

Silver Sponsors – BSCOS only

Allergan

Bronze Sponsors – Whole Event

Synthes

Bronze Sponsors – BSCOS only

B Braun Ltd
Osteotec
Voyant Health

Sponsors – Whole Event

Blackwells
STEPS